

Clinical and Microbiological Determinants of Ailing Dental Implants

Giorgio Tabanella, DDS, MS;* Hessam Nowzari, DDS, PhD;† Jorgen Slots, DDS, DMD, MS, PhD, MBA‡

ABSTRACT

Background: The failure of the host tissue to establish or maintain osseointegration around dental implants is due to either occlusal or parafunctional forces, premature loading, ill-directed stress, or microbial infection. The long-term failure rate of dental implants is generally 5–10%. Although a variety of etiologies of early peri-implant bone loss (from implant placement to 1-year post-loading) have been proposed, factors associated with late implant failures are less well understood but are probably related to both the peri-implant microbial environment and host factors. Discriminating between causes of implant failure is of importance for instituting a successful implant therapy.

Purpose: The objective of this cross-sectional split-mouth study was to identify clinical, radiographic, and bacterial characteristics of peri-implant disease sites.

Materials and Methods: Fifteen patients with bilateral implants (Brånemark®, Nobel Biocare AB, Göteborg, Sweden; and 3i™ implant systems, Implant Innovations Inc., Palm Beach Gardens, FL, USA) participated in the study. Sites with peri-implantitis (radiographic bone loss beyond the third implant thread) and peri-implant healthy tissues (radiographic bone level above the first implant thread) were identified in periapical radiographs using a long-cone paralleling projection technique. Microbiological identification was carried out using established anaerobic culture techniques. A descriptive statistics based on means and standard deviations was reported.

Results: Peri-implant bone loss was associated with the absence of radiographic crestal lamina dura, peri-implant pocket depth, pain on chewing, and the submucosal presence of the putative periodontopathogens *Tannerella forsythia*, *Campylobacter* species, and *Peptostreptococcus micros*. Pain was associated with *P. micros*, *Fusobacterium* species, and *Eubacterium* species.

Discussion and Conclusion: The absence of radiographic crestal lamina dura and the presence of suspected major periodontal pathogens seem to be associated to peri-implantitis.

KEY WORDS: oral implants, peri-implant bone loss, peri-implantitis, peri-implant tissue, predictors of ailing dental implants

The failure of the host tissue to establish or maintain osseointegration around dental implants is caused by either occlusal or parafunctional forces, premature loading, ill-directed stress,^{1–4} or microbial

infection.^{1,5,6} Implant failure can be divided chronologically into early (primary) failures (failure to establish osseointegration prior to loading) and late (secondary) failures (failure to maintain established osseointegration following loading).⁷ The long-term failure rate of dental implants is generally 5 to 10%.⁸ Implant failures with the Brånemark Implant System® (Nobel Biocare AB, Göteborg, Sweden), used in various anatomical locations and clinical situations, have been determined to be 7.7% over a period of 5 years.⁷ A distinction has been made between irreversible failing implants and ailing implants or implant complications. The designation of failed implants is assigned to mobile or exfoliated implants. Implant complications denote an increased risk for implant failure, but are

*Advanced periodontics, University of Southern California School of Dentistry, Los Angeles, CA, USA, and private practice, Rome, Italy; †program director, advanced periodontics, University of Southern California School of Dentistry, Los Angeles, CA, USA; ‡professor of periodontology and microbiology, University of Southern California School of Dentistry, Los Angeles, CA, USA

Reprint requests: Giorgio Tabanella, Via Delle Isole 9 Int. 4, 00198 Rome, Italy; e-mail: giorgio.tabanella@usc.edu

© 2008, Copyright the Authors
Journal Compilation © 2008, Blackwell Munksgaard

DOI 10.1111/j.1708-8208.2008.00088.x

either of only temporary significance or amenable to treatment.⁸ Discriminating between causes of implant failure is of importance for instituting a successful implant therapy.

The frequency of implants exhibiting peri-implantitis depends partly upon the implant treatment rendered. Overdentures, fixed complete dentures, and single-tooth replacement show peri-implantitis with frequencies ranging from 0.3 to 0.7%, while fixed partial dentures exhibit a mean frequency of peri-implantitis of 6.5%.⁹ The percentage of implants demonstrating bone loss of 2.5 mm or more is greater with overdentures (4.8%) and fixed complete dentures (3.8%) than with fixed partial dentures (1.0%) and single-tooth replacements (1.3%).⁹ Although a variety of etiologies of early peri-implant bone loss (from implant placement to 1-year post-loading) have been proposed,¹⁰ factors associated with late implant failures are less well understood but are probably related to both the peri-implant microbial environment and host factors.¹¹

The microbiota associated with unsuccessful implants was first presented by Rams and colleagues,^{12,13} who described a predominantly coccoid microbiota around successful implants and a spirochete-rich microbiota at ailing implants. Rosenberg and colleagues¹ found that spirochetes and motile rods averaged 42% of total bacterial morphotypes in implants ailing because of infection. Suspected periodontopathic microorganisms recovered by culture included *Peptostreptococcus micros*, *Fusobacterium* species, enteric Gram-negative rods, and yeasts.¹ Alcoforado and colleagues¹⁴ identified a peri-implantitis microflora consisting of *P. micros*, *Campylobacter rectus*, *Fusobacterium* species, *Prevotella intermedia*, and *Candida albicans*. Mombelli and colleagues¹⁵ studying ITI® and Brånemark fixtures identified *Porphyromonas gingivalis*, *P. intermedia*, *Fusobacterium*, and spirochetes in implant-associated deep pockets at 3 to 6 months following implant insertion. Leonhardt and colleagues¹⁶ found a submucosal flora in peri-implantitis sites predominated by *P. gingivalis*, *P. intermedia*, and *Actinobacillus actinomycetemcomitans*. More recent studies have essentially confirmed the findings of the early microbiological investigations of peri-implantitis.^{17,18}

Although various causes for failing implants have been described, most published reports do not distinguish between rates of peri-implant tissue destruction. Pathogenetically, rapidly progressing peri-implantitis

may resemble aggressive periodontitis, and slowly progressing peri-implantitis may approximate chronic periodontitis. To further determine the characteristics of a chronic type of peri-implantitis, this cross-sectional split-mouth study compared radiographic and clinical parameters, and levels of putative periodontopathogens in peri-implant healthy and disease sites of implants that had been in function for more than 2 years and had experienced tissue breakdown at or beyond the third implant thread.

MATERIALS AND METHODS

The present study included nine women and six men at 31 to 72 years of age (mean age, 56 years). Four subjects were fully edentulous. In the 15 study subjects, a total of 95 dental implants of various designs and lengths (8.5 to 15 mm) had originally been placed to support maxillary and mandibular fixed partial dentures, maxillary and mandibular overdentures, and mandibular hybrid types of restoration (Table 1). Each study subject exhibited an implant with pathologic bone loss (Table 2) and a contralateral healthy implant site (Table 3). Sixteen implants of the Brånemark system and 14 3i™ dental implants (Implant Innovations Inc., Palm Beach Gardens, FL, USA) were included in the study. All implants were threaded, had an external hex, and were made of pure titanium. The implants had been inserted at the advanced periodontics clinic at the University of Southern California, School of Dentistry. The institutional review board of the University of Southern California approved the study, and each subject provided written informed consent.

The patient selection criteria included the following: (1) presence of contralateral dental implants placed more than 2 years prior to the present study; (2) no mesial or distal cantilevers; (3) no immediate implant placement or loading; (4) no implants placed in grafted sites; (5) no clinically mobile implant; (6) no pregnant or nursing subjects; (7) no medically compromised subjects; (8) no subjects with periodontal or antibiotic treatment within the past 3 months; and (9) no subjects with acute systemic infections.

Implant sites were categorized as having peri-implantitis if radiographic bone loss clearly extended beyond the third thread of the implant, and as peri-implant healthy if radiographic bone level was above the

TABLE 1 Patient's Parameters

Patient	Year of Placement	History Periodontal Disease	Partially Edentulous Arch		Fully Edentulous Arch	Former Smoker	Age	Number Toothbrushings Per Day	Number of Implants	Number of Teeth	Restoration	Arch	Pre-medication	Antibiotics
			Yes	No										
1	2002	Yes	No	Yes	Yes	57	2	2	0	FPD	Mandible	Yes	Yes	
2	2002	No	Yes	No	No	33	1	1	29	FPD	Maxilla	No	No	
3	1990	Yes	Yes	No	Yes	65	1	9	6	FPD	Mandible	N/A	N/A	
4	1998	Yes	Yes	No	No	56	2	7	22	FPD	Maxilla	No	No	
5	2000	Yes	Yes	No	No	31	2	1	27	FPD	Mandible	N/A	N/A	
6	1999	Yes	Yes	No	No	67	1	3	23	FPD	Mandible	Yes	AMOX	
7	2003	Yes	Yes	No	No	69	2	4	18	FPD	Mandible	No	AMOX	
8	1993	No	No	Yes	No	65	1	10	0	Overdenture	Maxilla	N/A	AMOX	
9	2000	Yes	Yes	No	No	61	1	6	21	FPD	Maxilla	No	No	
10	1992	Yes	Yes	No	No	50	3	18	8	FPD	Mandible	N/A	N/A	
11	2002	No	No	Yes	No	63	1	2	0	Overdenture	Mandible	No	No	
12	2000	Yes	Yes	No	Yes	67	2	7	14	FPD	Mandible	N/A	N/A	
13	1990	No	No	Yes	Yes	61	2	5	0	Hybrid	Mandible	N/A	N/A	
14	1999	Yes	Yes	No	No	49	3	8	13	FPD	Maxilla	N/A	N/A	
15	1996	Yes	Yes	No	Yes	56	1	12	12	FPD	Maxilla	N/A	N/A	

AMOX = amoxicillin; FPD = fixed partial dentures; N/A = non-applicable.

TABLE 2 Disease Implant Site's Characteristics

Patient	Year of Placement	Area	Disease Implants	Symptomatic	Exposed Threads	Diameter	Length	Platform	Plaque-Index	Gingival Index	PPD at Sample Site	Lamina Dura	Bone Loss
1	2002	29	Brånemark Mk III	No	No	4	10	RP	1	2	9	No	Vertical
2	2002	8	Brånemark Mk III	Yes	Yes	3.75	10	RP	1	3	10	No	Vertical
3	1990	18	Brånemark SDCA	Yes	Yes	4	13	RP	3	2	5	No	Vertical
4	1998	4	Brånemark SDCA	Yes	Yes	4	15	RP	2	3	4	No	Horizontal
5	2000	19	Brånemark Mk III	Yes	No	5	13	RP	0	0	9	No	Vertical
6	1999	19	3i	Yes	Yes	5	10	RP	3	3	6	No	Vertical
7	2003	19	3i	No	No	4	8.5	TG	1	1	6	No	Horizontal
8	1993	6	Brånemark SDCA	No	No	3.75	13	RP	2	2	6	No	Horizontal
9	2000	15	3i	No	No	5	10	RP	1	2	7	No	Horizontal
10	1992	29	Brånemark Mk IV	Yes	Yes	5	8.5	RP	1	1	8	No	Horizontal
11	2002	27	Brånemark Mk IV	No	No	4	8.5	RP	3	3	6	No	Horizontal
12	2000	19	3i	No	No	5	10	RP	0	1	12	No	Vertical
13	1990	24	Brånemark SDCA	No	Yes	4	15	RP	1	1	4	No	Vertical
14	1999	3	Brånemark Mk IV	No	No	5	13	RP	1	1	4	No	Vertical
15	1996	4	Brånemark Mk III	Yes	Yes	3.75	15	RP	2	2	2	No	Horizontal

N/A = non-applicable; RP = regular platform; TG = transgingival.

TABLE 3 Healthy Implant Site's Characteristics

Patient	Year of Placement	Area	Healthy Implants	Symptomatic	Exposed Threads	Diameter	Length	Platform	Plaque-Index	Gingival Index	PPD at Sample Site	Lamina Dura	Bone Loss
1	2002	5	Brånemark Mk III	No	No	4	10	RP	0	0	5	Yes	N/A
2	2002	23	Brånemark Mk III	No	No	3.75	10	RP	1	1	2	Yes	N/A
3	1990	6	Brånemark SDCA	No	No	4	11.5	RP	3	1	4	Yes	N/A
4	1998	7	3i	No	No	3.25	15	RP	3	2	3	Yes	N/A
5	2000	30	Brånemark Mk III	No	No	5	13	RP	0	0	3	Yes	N/A
6	1999	30	3i	No	No	5	10	RP	1	1	3	Yes	N/A
7	2003	11	3i	No	No	4	8.5	TG	1	1	2	Yes	N/A
8	1993	29	Brånemark SDCA	No	No	3.75	13	RP	1	1	3	Yes	N/A
9	2000	30	Brånemark Mk III	No	No	3.75	15	RP	1	2	6	Yes	N/A
10	1992	5	Brånemark SDCA	No	No	4	15	RP	1	1	3	No	N/A
11	2002	22	Brånemark Mk IV	No	No	3.75	10	RP	3	3	4	No	N/A
12	2000	30	3i	No	No	5	10	RP	0	1	5	Yes	N/A
13	1990	22	Brånemark SDCA	No	No	4	15	RP	1	1	6	Yes	N/A
14	1999	14	Brånemark Mk IV	No	No	5	13	RP	1	1	4	Yes	N/A
15	1996	30	Brånemark Mk IV	No	No	3.75	11.5	RP	1	1	2	Yes	N/A

N/A = non-applicable; RP = regular platform; TG = transgingival.

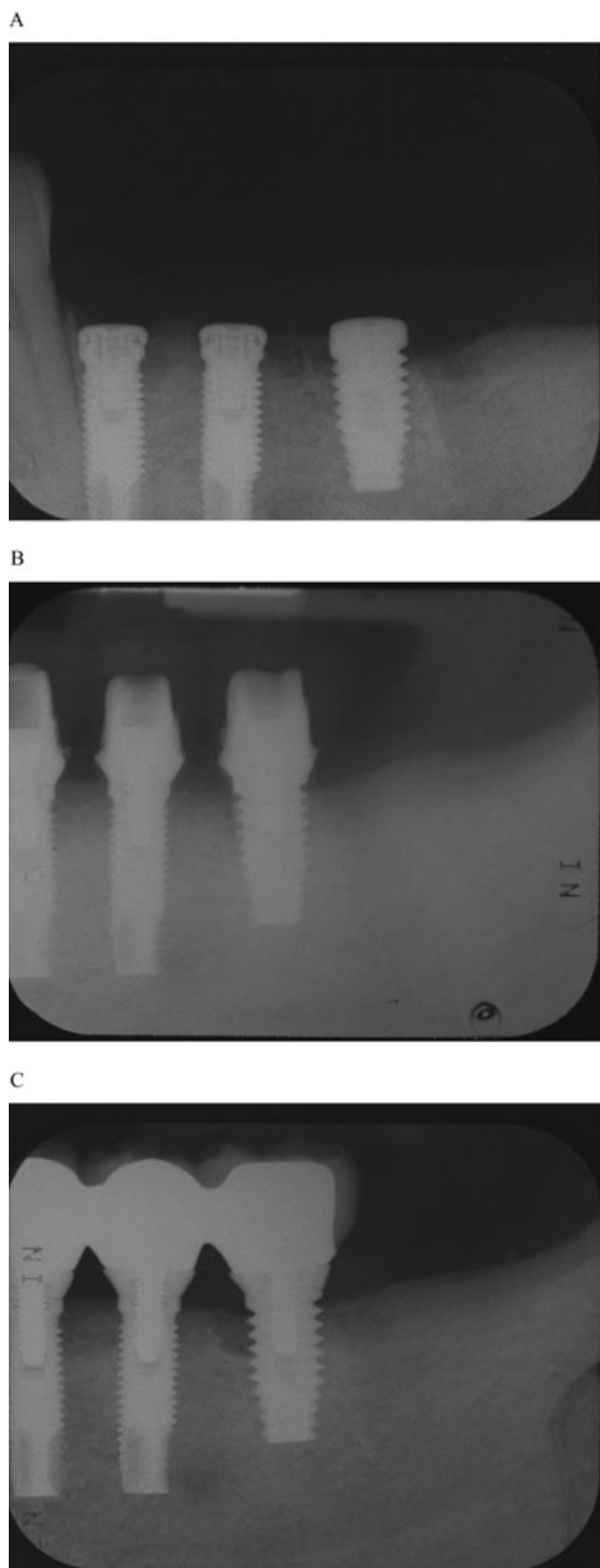


Figure 1 Radiographic aspect of ailing implants. (A) Postoperative radiograph at the time of implant placement. No peri-implant bone loss is present. (B) Postoperative radiograph at the time of abutment connection. No peri-implant bone loss is present. (C) Postoperative radiograph at 5 years. Peri-implant bone loss is extending beyond the third thread of the implant replacing tooth number 19.

the fixture threads serving as an internal reference.^{19,20} Periapical radiographs were obtained with a long-cone paralleling projection technique using a Rinn's film holder yielding a focus-film distance of approximately 25 cm, and a dental x-ray machine operating at 60 kVp. Film speed group E (Kodak Ektaspeed™, Eastman Kodak, Rochester, NY, USA) was used and developed immediately in an automatic developing machine. Only radiographs perpendicular to the long axis of the fixtures (ie, showing clearly visible fixture threads) were used for evaluation (see Figure 1).

The clinical examination included probing pocket depth, implant thread exposure, modified plaque index,²¹ gingival index,²² and bleeding on probing. Probing measurements were recorded at mesiobuccal, midbuccal, distobuccal, mesiolingual, midlingual, and distolingual surfaces using color-coded probes (PCV11PT, Hu-Friedy, Chicago, IL, USA). Probing pocket depth was assessed as the greatest distance between the gingival margin and the base of the peri-implant pocket. Probing measurements were rounded to the nearest millimeter. Bleeding on probing to the base of the peri-implant pocket was recorded as positive (ie, shown in red in Tables 2 and 3) if occurring within 30 seconds. A calibrated periodontist (G.T.), who was unaware of the microbiological data at the time of the clinical examination, performed the clinical measurements.

After removing the supragingival plaque, three fine endodontic paper points (Johnson & Johnson, East Windsor, NY, USA) were inserted to the depth of each study implant site for 10 seconds and transferred to viability medium Göteborg anaerobic III transport medium.²³ Microbiological samples were processed within 2 hours of collection. Anaerobic microbiological isolation and identification of putative periodontal pathogens were carried out following established procedures and with no knowledge of the source of the specimens. Samples were dispersed on a vortex mixer at the maximal setting for 45 seconds and were then 10-fold serially diluted in VMG I anaerobic dispersion solution.²³ Using a sterile bent glass rod, 0.1 mL aliquots

first thread of the implant (Figure 1). Immediately after implant insertion, radiographs showed maximally one implant thread exposed. Marginal bone level changes were recorded mesially and distally of the implants, with

from 10^3 to 10^5 dilutions were plated onto nonselective 4.3% brucella agar (BBL Microbiology Systems, Cockeysville, MD, USA) supplemented with 0.3% bactoagar, 5% defibrinated sheep blood, 0.2% hemolyzed sheep red blood cells, 0.0005% hemin, and 0.00005% menadione. The nonselective blood agar plates were incubated at 35°C in an anaerobic chamber (Coy Laboratory Products, Ann Arbor, MI, USA) containing 85% N₂–10% H₂–5% CO₂ for 10 days. Aliquots from undiluted and 10¹ dilution were also plated onto tryptic soy–serum–bacitracin–vancomycin (TSBV) medium for the culture of *A. actinomycetemcomitans*, enteric Gram-negative rods, and yeasts.²⁴ The TSBV medium was incubated in 10% CO₂ in air at 35°C for 4 days. Presumptive identification of representative colonies of each group of organisms that morphologically resembled the study species was performed according to methods described by Slots²⁵ and by use of a micromethod system (API® 20°, bioMérieux, Marcy l’Etoile, France). Organisms examined included *A. actinomycetemcomitans*, *P. intermedia/Prevotella nigrescens*, *P. gingivalis*, *Dialister pneumosintes*, *Tannerella forsythia*, *Campylobacter* species, *Fusobacterium* species, *P. micros*, enteric Gram-negative rods, and *Candida* species. Bacteria designated as major periodontal pathogens included *A. actinomycetemcomitans*, *P. gingivalis*, *D. pneumosintes*, and *T. forsythia*. The percentage recovery of periodontal pathogens was determined by the colony counts of each microbial taxon in relation to total viable counts.

A statistical analysis based on means and standard deviations of the microbiological parameters was reported.

RESULTS

The radiographically ailing implants had been in function for an average of 4 years (2 to 14 years). The average of remaining teeth per subject was 13.9. Prior to implant placement, 11 of the 15 study subjects had been treated for periodontal disease and were subsequently enrolled in a maintenance care program.

More teeth were present in the posterior than in the anterior dental area, and in the maxillary than in the mandibular arch. Subjects who had missing anterior teeth were more likely to be fully edentulous and rehabilitated with hybrid dentures or overdentures rather than with fixed partial dentures (see Table 1).

The number of ailing implants was greater in the mandible than in the maxilla, and in posterior than in

anterior sextants (see Table 2). Posterior sextants tended to show more vertical than horizontal peri-implant bony defects (see Table 2). The two implant systems studied revealed no statistically significant difference in bone loss pattern. However, peri-implantitis sites may be apparently related to the type of restoration, being the greatest amount of bone loss observed with overdentures, followed by fixed partial dentures and hybrid dentures.

Smoker and former smokers had significantly fewer teeth than nonsmokers (see Table 1). However, smoking status was not associated to peri-implantitis.

When peri-implant bone loss was reported, the radiographic lamina dura was always absent. Peri-implant bone loss sites showed an increased peri-implant pocket depth, symptoms, and the presence of *T. forsythia* ($4.53 \pm 3.27\%$), *Campylobacter* species ($4.23 \pm 3.57\%$), and *P. micros* ($3.54 \pm 4.26\%$). Sites with exposed implant threads but without increased peri-implant pocket depth had increased levels of *P. micros* and *Campylobacter* species.

Plaque index was positively correlated to age and negatively correlated to number of toothbrushings per day (see Tables 1–3). About 80% of implant sites exhibiting bone loss revealed plaque accumulation, but 54% of these sites showed only moderate to slight plaque. Bleeding on probing, suggestive of inflamed peri-implant tissues, was evident in 75% of implant sites with bone loss, but no correlation was found between bleeding on probing and the extent of bone breakdown in the two dental implant systems examined. Gingival (mucosal) index was positively correlated with the plaque index, *P. intermedia*, and *T. forsythia*, and was negatively correlated with number of toothbrushings per day. Higher gingival index values were reported when the lamina dura was absent, and in subjects with exposed implant threads and horizontal bone loss.

Bleeding on probing, wide diameter implants, and the absence of radiographic lamina dura seemed to be related to increased peri-implant pocket depth (see Table 2). The implant length was positively related to the duration of the implant in function, and negatively related to peri-implant pocket depth; in other words, in this small patient sample, longer implants had less bone loss and shallower pocket depth than shorter implants (see Table 2).

Total viable microbial counts (Figure 2), the percentage of total periodontopathogens (Figure 3), and the percentage of major periodontopathic bacteria

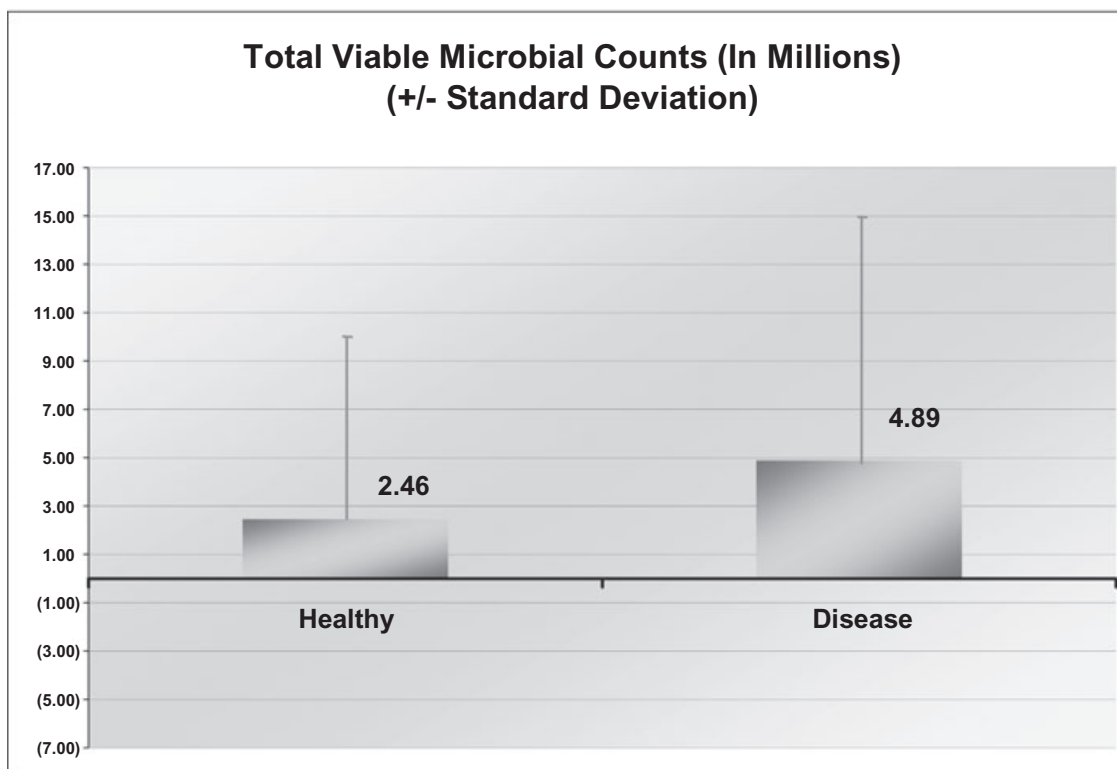


Figure 2 Total viable microbial counts in peri-implant sites.

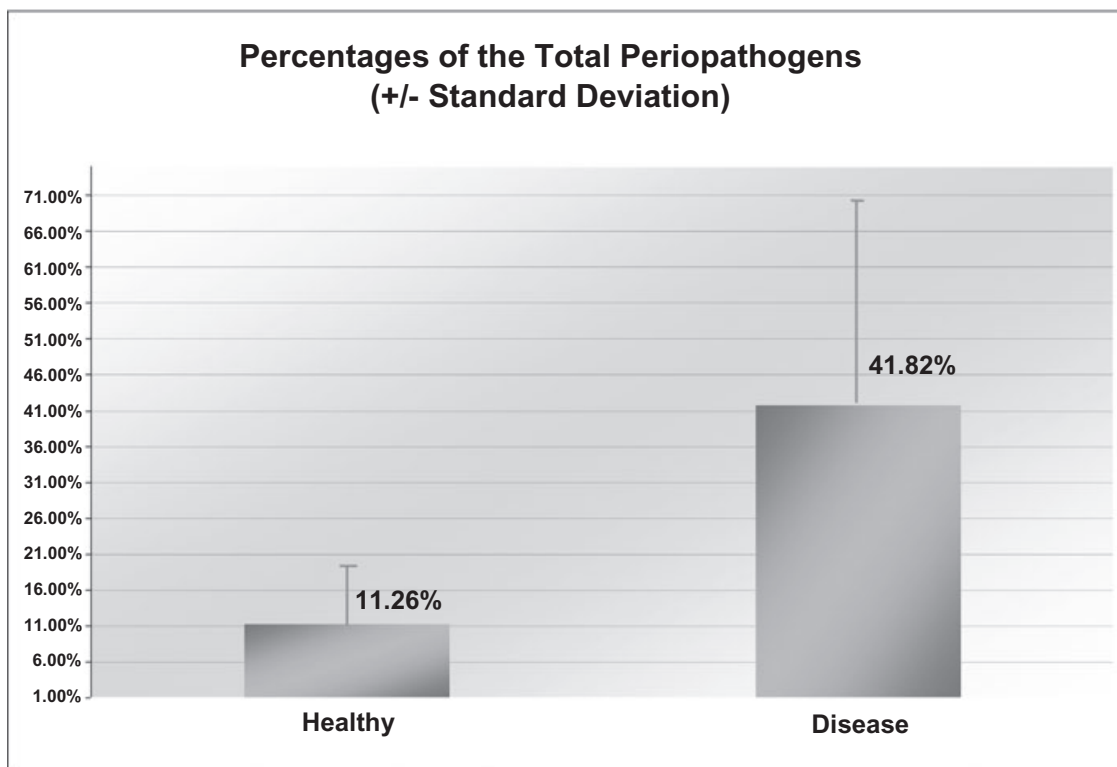


Figure 3 Percentage of total periodontopathogens in peri-implant sites.

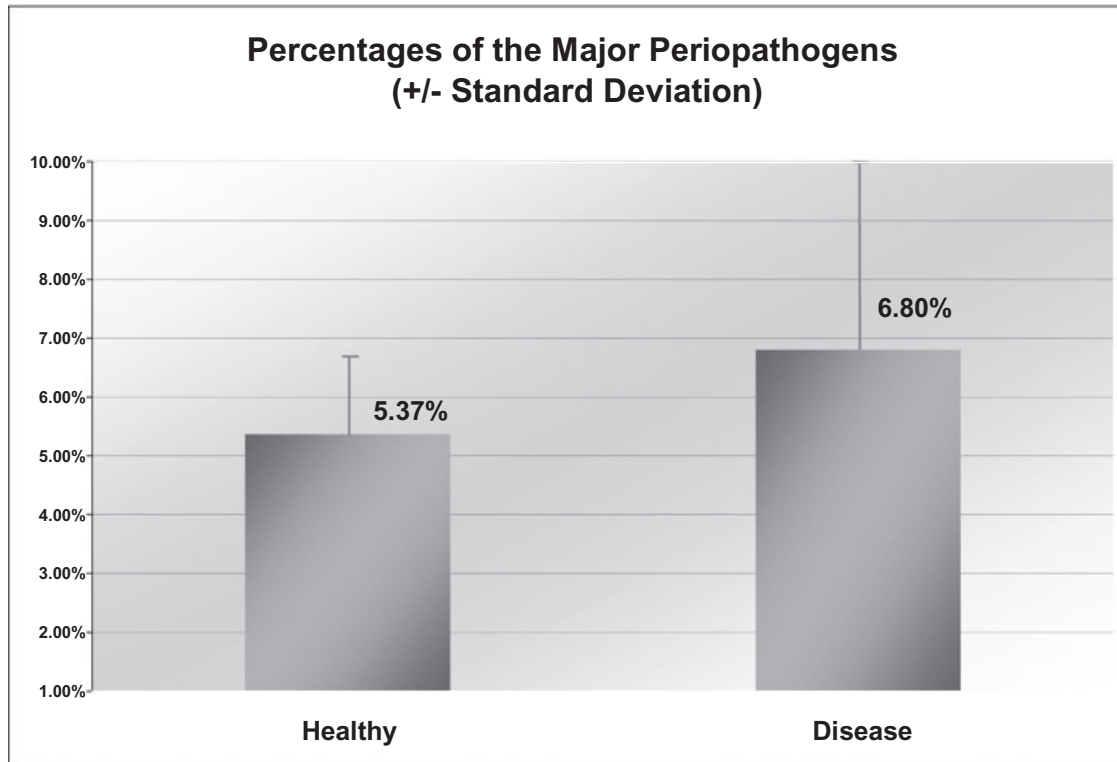


Figure 4 Percentage of major periodontopathogens in peri-implant sites.

(Figure 4) were higher in peri-implantitis than in healthy implant sites. *Fusobacterium* species, *T. forsythia*, *Campylobacter* species, and *P. micros* comprised the most common periodontopathogens in peri-implant bone loss sites (Figures 5 and 6).

Pain at implant sites was more likely to be found in partially rather than in fully edentulous subjects. Symptomatic implant sites tended to harbor *P. micros*, *Fusobacterium* species, and *Eubacterium* species. Furthermore, proportions of *P. micros* and *Campylobacter* species were higher in subjects who were premedicated with 2 g of amoxicillin at 1 hour prior to surgery. Compared to men, women exhibited more *P. intermedia*.

DISCUSSION

Interactions among physicochemical implant surfaces, colonizing bacteria, and host tissues are important determinants of long-term peri-implant tissue stability or peri-implant bone loss. Titanium implants are covered by a surface oxide layer of an approximate thickness of 2 to 5 nm, which displays amphoteric characteristics and supports cationic and anionic adsorption exchange.²⁶ Covalent, ionic, and hydrogen bonding

mediate the adsorption of highly reactive biopolymolecules from saliva or the gingival crevice fluid to the titanium oxide surface.²⁶ The surface characteristics of dental implants determine the adhesion potential of oral bacteria and host cells to implants.²⁶

The present study employed exposed implant threads in periapical radiographs to assess the health status of peri-implant tissues. Periapical radiographs are commonly used in clinical practice and in research to evaluate the outcome of dental implant treatment.^{20,27,28} A dental implant can serve as its own ruler in assessing radiographic bone height, which helps overcome problems with geometric foreshortening or elongational distortion of the radiographic image. This study found the absence of radiographic lamina dura to be a valuable parameter of peri-implantitis and increased peri-implant pocket depth, in a manner similar to that observed for periodontitis.²⁹

Implants of the Brånemark and 3i systems did not differ statistically in respect to the health status of peri-implant tissues. Although implant failures have been reported more frequently in the maxilla (about 77%),^{28,30} we found 9 of 15 (60%) ailing implants to be located in the mandible. However, we studied a select

Percentage of periodontopathogens

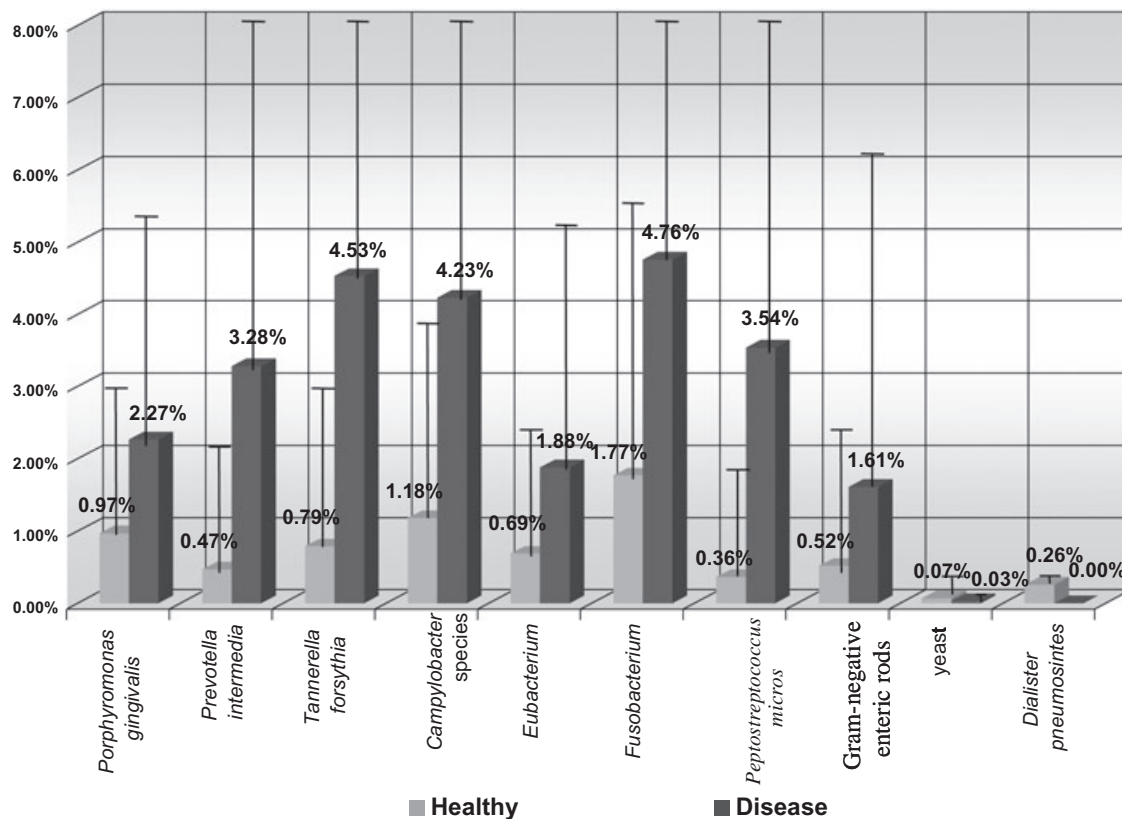


Figure 5 Percentage of periodontopathogenic bacterial species in peri-implant sites.

Total Number of Sites Harboring Periopathogens

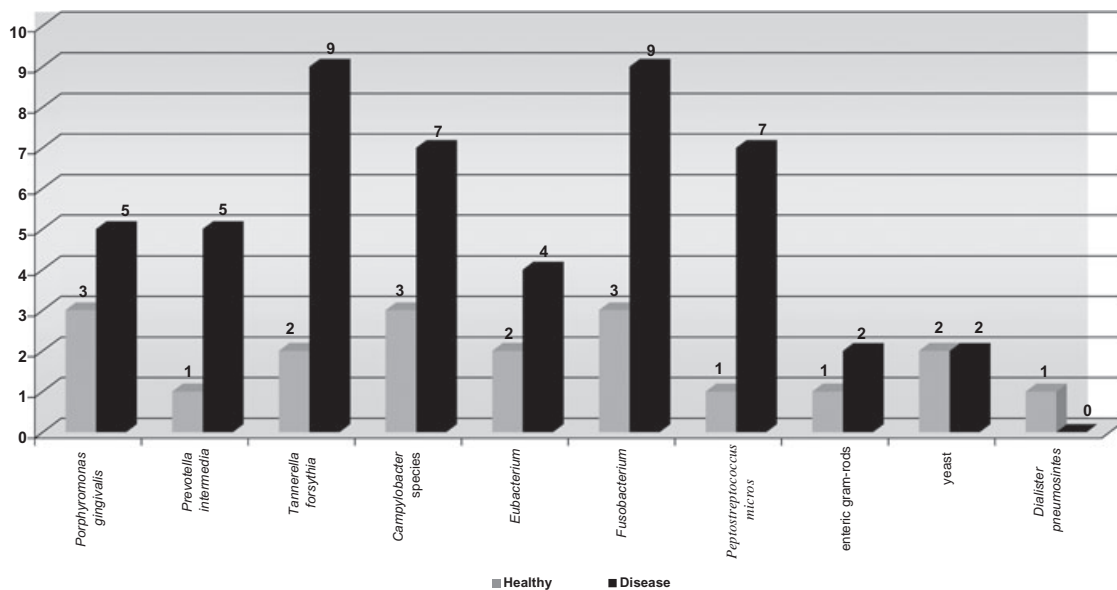


Figure 6 Total number of peri-implant sites harboring periodontopathogenic bacteria.

group of subjects and measured bone level around “surviving dental implants,” which are more likely to be found in the mandible than in the maxilla, maybe as a result of the relatively high density of the mandibular bone. The exclusion of already lost and mobile implants may have influenced the study outcome in favor of the maxilla. In the same way, the exclusion of peri-implant bone loss sites in patients who did not have contralateral peri-implant healthy sites may be bias.

A significant relationship was found between peri-implant bone loss and the type of restoration. Overdentures showed the greatest amount of horizontal bone loss, followed by fixed partial dentures and hybrid dentures. A likely explanation is that overdentures had the least favorable design to resist existing biomechanical forces. The restorative configuration of overdentures, which includes a bar to prevent free rotation of the prosthesis, may cause a twist loading of the implants and direct mechanical forces more laterally than axially, thereby contributing to a horizontal bone loss. Also, maxillary and mandibular overdentures may have been used in those study patients who had jawbones of poor quality and quantity, and few remaining natural teeth, even in the face of an increased risk of peri-implant bone breakdown.³¹ The type of implant treatment thus constitutes another parameter of potential importance for peri-implant bone loss.

Poor jawbone quality in combination with low jawbone volume may also explain the increased peri-implant pocket depth with short and wide-body implant fixtures (see Table 2). Short implants tend to be placed in sites having insufficient bone to support long implants.³¹ Short implants may tend to experience suboptimal stability, and therefore show a greater loss of crestal bone and deeper pockets than long implants. Also, the placement of wide-body implants may lead to bony fenestration or dehiscence and, subsequently, the formation of deep peri-implant pockets, unless the site is previously augmented. The predominance of anaerobic pathogenic bacteria in deep peri-implant sites may further accelerate tissue breakdown.³² The possible relationship between implant design and the composition of the peri-implant microbial flora needs to be investigated further.

Smoking status was found to be related to an increased number of missing teeth, which is in accordance with several studies examining risk factors for tooth loss.^{33,34} However, smoking status was not statistically associated with peri-implant bone loss. Although

smoking probably has an adverse effect on the initial survival rate of implants,³⁵ our results suggest that smoking may not constitute a major determinant of late peri-implant bone loss.

An inherent problem with the use of titanium and other biomaterials is the development of bacterial biofilms on their surfaces.³⁶ We found the most common periodontopathic bacteria in peri-implant sites to be *Fusobacterium* and *T. forsythia*, followed by *Campylobacter* and *P. micros*. Our study did not support the findings of Leonhardt and colleagues¹⁶ who showed a predominance of *P. gingivalis*, *P. intermedia*, and *A. actinomycetemcomitans* in peri-implantitis sites. Mombelli and colleagues¹⁵ also recovered *P. gingivalis* and *P. intermedia* from peri-implantitis lesions. We did not recover *A. actinomycetemcomitans* from any implant site. Differences in study populations and in the rate of peri-implant tissue breakdown may explain the differing microbiological results. Our study subjects had received regular maintenance therapy and exhibited maximally four exposed implant threads, indicating a slowly progressing type of peri-implant tissue destruction.

We found the modified gingival index to be positively associated with increased numbers of *T. forsythia* and *P. intermedia*, and peri-implant bone loss with significantly elevated levels of *T. forsythia*, *Campylobacter*, and *P. micros*. In contrast to previous studies,³⁷ we recovered *T. forsythia* not only from peri-implantitis sites but also from solely mucositis sites. Our data suggest that *P. intermedia*, which is associated with acute³⁸ and chronic gingivitis,³⁹ is also involved in the development of mucositis around implants.

Implants in partially edentulous subjects exhibited more symptomatology than implants in completely edentulous subjects. Periodontal pathogens translocate from natural teeth to implants in the same mouth¹⁸ and tend to occur in greater numbers around implants in partially edentulous than in fully edentulous subjects.^{17,40,41} It is possible that “symptomatogenic” periodontal bacteria, such as *P. micros*, *Fusobacterium*, and *Eubacterium*, had seeded from natural teeth to implants in our study subjects. However, we found no significant difference in the percentage of pathogenic bacteria between partially and completely edentulous subjects, or between subjects who did or did not have a history of periodontal disease. Again, an efficient initial antimicrobial periodontal treatment and maintenance program may have suppressed resident

periodontopathogenic bacteria in the periodontitis patients studied. The observed symptomatology may also have been because of bacteria other than those studied, or possibly to an unidentified herpesvirus infection.⁴²

A curious finding was the elevated *Campylobacter* and *P. micros* counts in subjects who had received amoxicillin at the time of implant surgery. It is possible that beta-lactamase activity in *Campylobacter* species and *P. micros* strains can account for the elevated levels of the organisms.⁴³ Our finding of higher counts of *P. intermedia* in peri-implantitis sites of women than of men is consistent with female sex hormones being growth factors for the organism.^{43,44} Although we reported higher percentages of *Fusobacterium* in disease sites, it is reasonable to believe that the bacterium may co-aggregate *P. intermedia*, *P. gingivalis*, and other periodontal pathogens, thereby participating in the formation of a pathogenic anaerobic polymicrobial community rather than being highly pathogenic itself.^{45,46}

In conclusion, the present study points to the absence of a radiographic lamina dura as a significant indicator of peri-implantitis and increased peri-implant pocket depth. In addition, *T. forsythia*, *Campylobacter* species, *P. micros*, *Fusobacterium* species, and symptomatic implant sites showed to be significant indicators of peri-implantitis. However, all indicators may also act as a combination of factors which may influence implant survival. Although our findings draw attention to the desirability of removing or markedly suppressing these bacteria from peri-implant sites, these indicators need to be investigated further.

ACKNOWLEDGMENTS

The authors thank Dr. Winston Chee for his support in the clinical aspects of the study.

REFERENCES

- Rosenberg ES, Torosian JP, Slots J. Microbial differences in 2 clinically distinct types of failures of osseointegrated implants. *Clin Oral Implants Res* 1991; 2:135–144.
- Brånemark PI. Introduction to osseointegration. In: Brånemark PI, ed. *Tissue-integrated prosthesis: osseointegration in clinical dentistry*. Chicago, IL: Quintessence, 1985:11–76.
- van Steenberghe D, Lekholm U, Bolender C, et al. The applicability of osseointegrated oral implants in the rehabilitation of partial edentulism: a prospective multicenter study on 558 fixtures. *Int J Oral Maxillofac Implants* 1990; 5:272–281.
- Zarb GA, Schmitt A. The longitudinal clinical effectiveness of osseointegrated dental implants: the Toronto study, part III: problems and complications encountered. *J Prosthet Dent* 1990; 64:53–61.
- Apse P. Cross-sectional and microbiological investigation of peri-implant and periodontal status. *J Dent Res* 1988; 67(Spec Issue):287. (Abstr)
- Newman MG, Flemming TF. Periodontal considerations of implant and implant associated microbiota. *J Dent Educ* 1988; 52:737–744.
- Esposito M, Hirsch J, Lekholm U, Thomsen P. Biological factors contributing to failures of osseointegrated implants. I. Success criteria and epidemiology. *Eur J Oral Sci* 1998; 106:527–551.
- Esposito M, Hirsch JM, Lekholm U, Thomsen P. Biological factors contributing to failures of osseointegrated oral implants (II). Etiopathogenesis. *Eur J Oral Sci* 1998; 106:721–764.
- Berglundh T, Persson L, Klinge B. A systematic review of the incidence of biological and technical complications in implant dentistry reported in prospective longitudinal studies of at least 5 years. *J Clin Periodontol* 2002; 29(Suppl 3):197–212.
- Oh TG, Yoon J, Misch CE, Wang HL. The causes of early implant bone loss: myth or science? *J Periodontol* 2002; 73:322–333.
- Quirynen M, De Soete M, van Steenberghe D. Infectious risk for oral implants: a review of the literature. *Clin Oral Implants Res* 2002; 13:1–19.
- Rams TE, Link CC. Microbiology of failing dental implants in humans: electron microscopic observations. *J Oral Implantol* 1983; 11:93–100.
- Rams TE, Roberts TW, Tatum H Jr, Keyes PH. The subgingival microbial flora associated with human dental implants. *J Prosthet Dent* 1984; 51:529–534.
- Alcoforado GA, Rams TE, Feik D, Slots J. Microbial aspects of failing osseointegrated dental implants in humans. *J Periodontol* 1991; 10:11–18.
- Mombelli A, Marxer M, Gaberthuel T, Grunder U, Lang NP. The microbiota of osseointegrated implants in patients with a history of periodontal disease. *J Clin Periodontol* 1995; 22:124–130.
- Leonhardt A, Adolfsson B, Lekholm U, Wickström M, Dahlin G. A longitudinal microbiological study on osseointegrated titanium implants in partially edentulous patients. *Clin Oral Implants Res* 1993; 4:113–120.
- George K, Zafropoulos GG, Murat Y, Spiekermann H, Nisengard RJ. Clinical and microbiological status of osseointegrated implants. *J Periodontol* 1994; 65:766–770.
- Lee KH, Maiden MF, Tanner AC, Weber HP. Microbiota of successful osseointegrated dental implants. *J Periodontol* 1999; 70:131–138.
- Hollender L, Rockler B. Radiographic evaluation of osseointegrated implants in the jaws. *Dentomaxillofac Radiol* 1980; 9:91–95.

20. Brägger U. Radiographic parameters for the evaluation of peri-implant tissues. *Periodontology* 2000 1994; 4:87–97.
21. Mombelli A, Van Oosten MA, Schurch E, Lang NP. The microbiota associated with successful or failing osseointegrated titanium implants. *Oral Microbiol Immunol* 1987; 2:145–151.
22. Løe H, Silness J. Periodontal disease in pregnancy. I. Prevalence and severity. *Acta Odontol Scand* 1963; 21:533–551.
23. Möller ÅJR. Microbiological examination of root canals and periapical tissues of human teeth. *Methodological studies. Odontol Tidskr* 1966; 74:S1–380.
24. Slots J. Selective medium for isolation of *Actinobacillus actinomycetemcomitans*. *J Clin Microbiol* 1982; 15:606–609.
25. Slots J. Rapid identification of important periodontal microorganism by cultivation. *Oral Microbiol Immunol* 1986; 1:48–57.
26. Grossner-Schreiber B, Griepentrog M, Haustein I, et al. Plaque formation on surface modified dental implants. An *in vitro* study. *Clin Oral Implants Res* 2001; 12:543–551.
27. Gröndahl K, Lekholm U. The predictive value of radiographic diagnosis of implant instability. *Int J Oral Maxillofac Implants* 1997; 12:59–64.
28. Lekholm U, van Steenberghe D, Herrmann I, et al. Osseointegrated implants in the treatment of partially edentulous jaws: a prospective 5-year multicenter study. *Int J Oral Maxillofac Implants* 1994; 9:627–635.
29. Rams TE, Listgarten MA, Slots J. Utility of radiographic crestal lamina dura for predicting periodontitis disease-activity. *J Clin Periodontol* 1994; 21:571–576.
30. Jemt T, Chai J, Harnett J, et al. A 5-year prospective multicenter follow-up report on overdentures supported by osseointegrated implants. *Int J Oral Maxillofac Implants* 1996; 11:291–298.
31. Herrmann I, Lekholm U, Holm S, Kultje C. Evaluation of patient and implant characteristics as potential prognostic factors for oral implant failures. *Int J Oral Maxillofac Implants* 2005; 20:220–230.
32. Edwardsson S, Bing M, Axtelius B, Lindberg B, Söderfeldt B, Attström R. The microbiota of periodontal pockets with different depths in therapy-resistant periodontitis. *J Clin Periodontol* 1999; 26:143–152.
33. Krall EA, Dawson-Hughes B, Garvey AJ, Garcia RI. Smoking, smoking cessation, and tooth loss. *J Dent Res* 1997; 76:1653–1659.
34. Axelsson P, Paulander J, Lindhe J. Relationship between smoking and dental status in 35-, 50-, 65-, and 75-year-old individuals. *J Clin Periodontol* 1998; 25:297–305.
35. Bain C, Moy P. The association between the failure of dental implants and cigarette smoking. *Int J Oral Maxillofac Surg* 1993; 8:609–615.
36. Gristina A. Biomaterial-centered infection: microbial adhesion versus tissue integration. *Clin Orthop Relat Res* 1987; 427:4–12.
37. Lai C-H, Listgarten MA, Shirakawa M, Slots J. *Bacteroides forsythus* in adult gingivitis and periodontitis. *Oral Microbiol Immunol* 1987; 2:152–157.
38. Loesche WJ, Syed SA, Laughon BE, Stoll J. The bacteriology of acute necrotizing ulcerative gingivitis. *J Periodontol* 1982; 53:447–456.
39. Tanner ACR, Haffer C, Bratthall GT, Visconti RA, Socransky SS. A study of the bacteria associated with advancing periodontitis in man. *J Clin Periodontol* 1979; 6:278–307.
40. Meffert RM. Periodontitis vs. peri-implantitis: the same disease? The same treatment? *Crit Rev Oral Biol Med* 1996; 7:278–291.
41. Quirynen M, Listgarten MA. The distribution of bacterial morphotypes around natural teeth and titanium implants and modum Brånemark. *Clin Oral Implants Res* 1990; 1:8–12.
42. Slots J, Nowzari H, Sabeti M. Cytomegalovirus infection in symptomatic periapical pathosis. *Int Endod J* 2004; 37:519–524.
43. Nakagawa S, Fujii H, Machida Y, Okuda K. A longitudinal study from prepuberty to puberty of gingivitis. Correlation between the occurrence of *Prevotella intermedia* and sex hormones. *J Clin Periodontol* 1994; 21:658–665.
44. Kornman KS, Loesche WJ. The subgingival microbial flora during pregnancy. *J Periodontal Res* 1980; 15:111–122.
45. Kolenbrander PE. Oral microbial communities: biofilms, interactions, and genetic systems. *Annu Rev Microbiol* 2000; 54:413–437.
46. Socransky SS, Haffajee AD, Dzink JL, Hillman JD. Associations between microbial species in subgingival plaque samples. *Oral Microbiol Immunol* 1988; 3:1–7.